

Metabolic differences between primary and recurrent human brain tumors: a ^1H NMR spectroscopic investigation

Fritz-Georg Lehnhardt,¹ Christian Bock,¹ Gabriele Röhn,² Ralf-Ingo Ernestus² and Mathias Hoehn^{1*}

¹Max-Planck-Institute for Neurological Research, Cologne, Germany

²Department of Neurosurgery, University of Cologne, Cologne, Germany

Received 23 April 2004; Revised 26 April 2005; Accepted 4 May 2005

ABSTRACT: High-resolution proton magnetic resonance spectroscopy was performed on tissue specimens from 33 patients with astrocytic tumors (22 astrocytomas, 11 glioblastomas) and 13 patients with meningiomas. For all patients, samples of primary tumors and their first recurrences were examined. Increased anaplasia, with respect to malignant transformation, resulting in a higher malignancy grade, was present in 11 recurrences of 22 astrocytoma patients. Spectroscopic features of tumor types, as determined on samples of the primary occurrences, were in good agreement with previous studies. Compared with the respective primary astrocytomas, characteristic features of glioblastomas were significantly increased concentrations of alanine (Ala) ($p = 0.005$), increased metabolite ratios of glycine (Gly)/total creatine (tCr) ($p = 0.0001$) and glutamate (Glu)/glutamine (Gln) ($p = 0.004$). Meningiomas showed increased Ala ($p = 0.02$) and metabolite ratios [Gly, total choline (tCho), Ala] over tCr ($p = 0.001$) relative to astrocytomas, and *N*-acetylaspartate and myo-inositol were absent. Metabolic changes of an evolving tumor were observed in recurrent astrocytomas: owing to their consecutive assessments, more indicators of malignant degeneration were detected in astrocytoma recurrences (e.g. Gly, $p = 0.029$; tCho, $p = 0.034$; Glu, $p = 0.015$; tCho/tCr, $p = 0.001$) in contrast to the comparison of primary astrocytomas with primary glioblastomas. The present investigation demonstrated a correlation of the tCho-signal with tumor progression. Significantly elevated concentrations of Ala ($p = 0.037$) and Glu ($p = 0.003$) and metabolite ratio tCho/tCr ($p = 0.005$) were even found in recurrent low-grade astrocytomas with unchanged histopathological grading ($n = 11$). This may be related to an early stage of malignant transformation, not yet detectable morphologically, and emphasizes the high sensitivity of ^1H NMR spectroscopy in elucidating characteristics of brain tumor metabolism. Copyright © 2005 John Wiley & Sons, Ltd.

KEYWORDS: human brain tumors; astrocytoma; glioma; recurrent tumors; ^1H NMR spectroscopy

INTRODUCTION

^1H NMR spectroscopy (^1H MRS) has been used extensively to characterize intracranial neoplasms *in vivo*. Several detectable metabolites contribute to the distinction between normal brain and brain tumors and help in the investigation of metabolic alterations of different tumor types.^{1–5} *In vivo* brain tumors show an increased concentration of the total choline signal [tCho = the sum of phosphocholine (PCho, a precursor of membrane phospholipids), glycerophosphocholine (GPCho, a degradation product of membrane phospholipids) and free choline] and also the ratio of tCho over total creatine [tCr = the sum of phosphocreatine (PCr) and creatine (Cr)] compared with the contralateral brain hemisphere. This has been taken to reflect greater membrane synthesis, increased cellularity and rapid cell membrane turnover

during cell growth.^{6–10} Moreover, the *in vivo* ^1H MRS tCho signal and the ratio tCho/tCr are assumed to be related to the degree of malignancy,^{2,3,11–13} whereas some authors found these values to be non-discriminative between low- and high-grade gliomas.^{10,14,15}

The *in vivo* *N*-acetyl methyl signal at 2.01 ppm is mainly attributed to *N*-acetylaspartate (NAA), which is reduced in gliomas and mostly absent in meningiomas.¹⁶ As NAA serves as a marker of neural cell density, its reduction is evidently caused by a loss of neural cells.^{7,17,18} Cr decreases in highly malignant gliomas to some extent and is low or not detectable in meningiomas.^{13,19,20} The lactate (Lac) signal can be observed in brain tumors, but its association with highly malignant tumors was not shown unequivocally.¹³

To clarify such *in vivo* findings, several parallel studies were performed with spectral analysis of tissue extracts obtained from biopsy specimens or after tumor removal.^{10,12,14,21,22} Such investigations were helpful for the clarification of resonance assignments and for the validation of the quantification procedures of *in vivo* ^1H NMR data. Particularly the *in vivo* contributions to the tCho signal are still controversial. The tCho concentration of the respective tissue volume analyzed *in vitro* was

*Correspondence to: M. Hoehn, Max-Planck Institut für Neurologische Forschung, Gleuelerstrasse 50, D-50931 Köln, Germany.
E-mail: mathias@mpin-koeln.mpg.de

Abbreviations used: GPCho, glycerophosphocholine; Lac, lactate; MRS, magnetic resonance spectroscopy; NAA, *N*-acetylaspartate; PCA, perchloric acid; PCho, phosphocholine; PCr, phosphocreatine; PtdCho, phosphatidylcholine; SM, sphingomyelin; tCHO, total choline; tCr, total creatine; TSP, 3-(trimethylsilyl)propionic acid.

lower than expected from the *in vivo* data. Some authors assumed this could at least partially be due to the loss of mobile choline headgroups of the phospholipid phosphatidylcholine during the extraction procedure.^{20,23,24}

In vitro ¹H NMR studies have been reported for a wide range of human brain tumors with different degrees of malignancy. Owing to the higher magnetic field strength of *in vitro* NMR systems, the sensitivity and spectral resolution are greatly improved, increasing the number of detectable metabolites. Hence further specifications of abnormalities in tumor metabolism including less concentrated metabolites such as alanine (Ala), glutamine (Gln) or myo-inositol (myo-Ino) have been reported. With this spectral information, different tumor types have been characterized and tumor malignancy has been determined in gliomas.^{19,20,25–27}

It is well known that low-grade gliomas often undergo malignant transformation into tumors of higher malignancy during their development of recurrence. The malignancy potential in terms of biological aggressiveness in recurrent gliomas is considered to be that of malignant gliomas, a situation which is associated with poor prognosis as related to reduced survival times.^{3,13,28–30} The comparison of metabolite profiles in tissue samples of primary and recurrent gliomas with or without changes in malignancy will therefore provide further insight into mechanisms of malignant transformation. In the present study, we hypothesized that tumor recurrence is accompanied by an evolving tumor metabolism, leading to specific alterations of the metabolic tumor profile, and that these metabolic alterations can be observed using high resolution *in vitro* ¹H NMR spectroscopy.

In the present ¹H NMR study, biopsy specimens from patients who had undergone surgical removal of brain tumors on at least two occasions had been analyzed, providing samples of primary tumors and their respective recurrent tumors. The serial measurement of primary and recurrent tumors from the same patients enabled us to obtain biochemical information on an evolving tumor metabolism. To the best of our knowledge, this is the first *in vitro* ¹H NMR study evaluating grading-dependent alterations of metabolism in tumor recurrence of gliomas.

MATERIALS AND METHODS

Origin of specimens

Tissue specimens of brain tumors were obtained from a large tissue bank of brain tumor biopsies collected during surgery at the Department of Neurosurgery, University of Cologne. These neurosurgical samples had been taken during conventional microsurgical operations for tumor removal. Tumors were studied after informed consent of the patients had been obtained according to the Helsinki Declaration of ethical requirements.

Patient group profiles

Patient group profiles are given in Table 1. Samples of the primary brain tumor and its first recurrence were available from all patients.

Specimens from 22 patients with astrocytomas were examined. These patients were further divided into three groups, depending on the grade of malignancy in the recurrent tumor: World Health Organization (WHO) grade II, III and IV, respectively. The first group (i) comprised 11 patients with low-grade (WHO grade II) primary astrocytomas without changes in histopathological grading during recurrence. The second group (ii) consisted of five patients with anaplastic (WHO grade III) recurrences. The third group (iii) was based on six patients with secondary glioblastoma (WHO grade IV), but varying primary grades: four of them with anaplastic and two with low-grade primary astrocytomas.

Furthermore, primary and recurrent tumors from 11 patients with primary glioblastomas (WHO grade IV) and 13 patients with meningiomas were investigated. Finally, one sample of peritumoral, non-neoplastic human brain, derived from part of the tissue removal of an oligodendroglioma, was investigated.

Sample preparation

All specimens were frozen in liquid nitrogen immediately after excision and stored at -80°C . Histopathological

Table 1. Patient group profiles, each patient contributing one primary and its first recurrent tumor

Tumor type	Age (years) ^a	Patients	Recurrence ^b	Malignant transformation ^c
Astrocytomas (Grade II–IV) ^d	39 ± 11	22	22 ± 16	11
(i) GII → GII	36 ± 9	11	23 ± 17	0
(ii) GII → GIII	35 ± 14	5	25 ± 8	5
(iii) GII/III → GIV	46 ± 10	6	17 ± 15	6
Glioblastomas (GIV)	58 ± 9	11	10 ± 6	—
Meningiomas (GII)	55 ± 19	13	15 ± 13	0

Astrocytomas are subdivided due to grading changes in recurrence, determined by WHO grading criteria (Grade II–IV).

^aAge at time of primary surgery, mean ± SD.

^bPostoperative intervals in months until second surgery, mean ± SD.

^cNumber of malignant degenerations in recurrence, based on histopathological classifications.

^dSubgroups according to histopathological grading in tumor recurrence; GIV comprises six secondary glioblastomas, evolved from prior astrocytomas (GII–III).

diagnosis was performed on 10 μm thin cryostat sections after hematoxylin–eosin staining and followed the WHO classification system.³¹ Tissue samples were taken from the same part of the tumor as used for the cryostat section for histological analysis. The samples ranged from 50 to 150 mg wet weight. Frozen tissue was immediately homogenized after addition of 6% chilled perchloric acid (0.2–0.5 mL, depending on tissue weight). After 20 min of storage on ice, samples were centrifuged at 16 000 g for 4 min. The supernatant was collected and the pellet was resuspended in perchloric acid and treated as described above. The combined supernatant was carefully neutralized with KOH, centrifuged to remove precipitated KClO_4 , lyophilized and stored at -80°C . All chemicals used were obtained from Sigma (Deisenhofen, Germany).

^1H NMR spectroscopy

All spectra were recorded on a WM300 high-resolution NMR spectrometer (Bruker, Karlsruhe, Germany). The sample tube was spun at 15 Hz. Proton spectra were collected at 300.09 MHz.

Perchloric acid (PCA) extracts of the tissues were redissolved in 0.5 mL of deuterium oxide and the pH was checked for neutrality. The samples were then transferred into a 5 mm diameter NMR tube. The spectral parameters were as follows: 360 acquisitions, 16K data points, 90° pulse angle, 2200 Hz sweep width, relaxation delay 1.0 s and acquisition time 3.71 s, resulting in a repetition time of 4.71 s and an experimental averaging time of 28 min. 3-(Trimethylsilyl)propionic acid (TSP) was used as an external standard for sample quantification; chemical shift referencing was achieved relative to the creatine signal at 3.04 ppm. No line broadening was applied. To assess potential T_1 -dependent signal damping before integration, comparison of the signal intensities of fully relaxed spectra ($\text{TR} = 30$ s) with the respective signal intensities using a repetition time of 4.71 s was performed. No significant T_1 -dependent saturation regarding the signal intensities of the relevant compounds (Gly, tCho, tCr, Glu, Gln, Ala) was observed. The integration values were normalized to the number of contributing protons per molecule and to tissue weight. Quantification was performed by comparing the integrated TSP signal with the signal of interest in the tumor spectrum after baseline correction. Absolute concentrations are given as means \pm SD in $\mu\text{mol/g}$ wet weight.

Assignment of resonances

All signal assignments in the ^1H NMR spectra were made by adding pure substances of individual metabolites to sample solution and comparing the peak heights before and after addition. The resulting values (ppm) were confirmed by comparison with literature assignments.^{23,32,33}

Statistical analysis

One-way-analysis of variance (ANOVA) was used to perform an F -test for the determination of statistical significance among the primary tumors of the three tumor types by group means. Groupings between primary and recurrent tumors within a tumor type were compared at the level of the individual metabolites using a two-tailed t -test. The significance of both tests was determined at the $p < 0.05$ level.

RESULTS

Patient group profiles

In good agreement with epidemiological studies³⁴ on large groups, the average age of patients in the astrocytoma group is approximately 16 and 18 years younger than that of patients with meningiomas and glioblastomas, respectively (Table 1). Patients with secondary glioblastomas, evolved from prior astrocytomas, are somewhat older at time of primary surgery. The postoperative interval represents the time elapsed between the first surgery on the brain tumor and operation on the recurrent tumor. The mean postoperative interval of astrocytomas is about 1 year longer than that of glioblastomas, whereas this period is slightly decreased in secondary glioblastomas. Early recurrence of meningiomas may be mainly influenced by incomplete excision owing to the location of the tumor. Increased histological malignancy grade, referring to malignant transformation, was present in 11 recurrent tumors from 22 patients with primary astrocytomas, including six secondary glioblastomas.

Normal brain

The high-field region (1.0–4.5 ppm) of ^1H MR spectra obtained from non-neoplastic peritumoral tissue is shown in Fig. 1. In agreement with histology, the tissue sample showed spectroscopic features as described for normal brain,^{12,23,35,36} with a wide range of metabolites (Table 2). The main features of normal brain as opposed to brain tumor spectra were high concentrations of NAA, Asp and myo-Ino, in parallel with low concentrations of Ala, Gly and tCho; Lac was greatly increased because of the unavoidable time of anaerobic glycolysis during tissue excision and was therefore of no discriminative value.

Distinction between primary astrocytomas, glioblastomas and meningiomas

Differences between the representative spectra of primary astrocytomas, glioblastomas and meningiomas

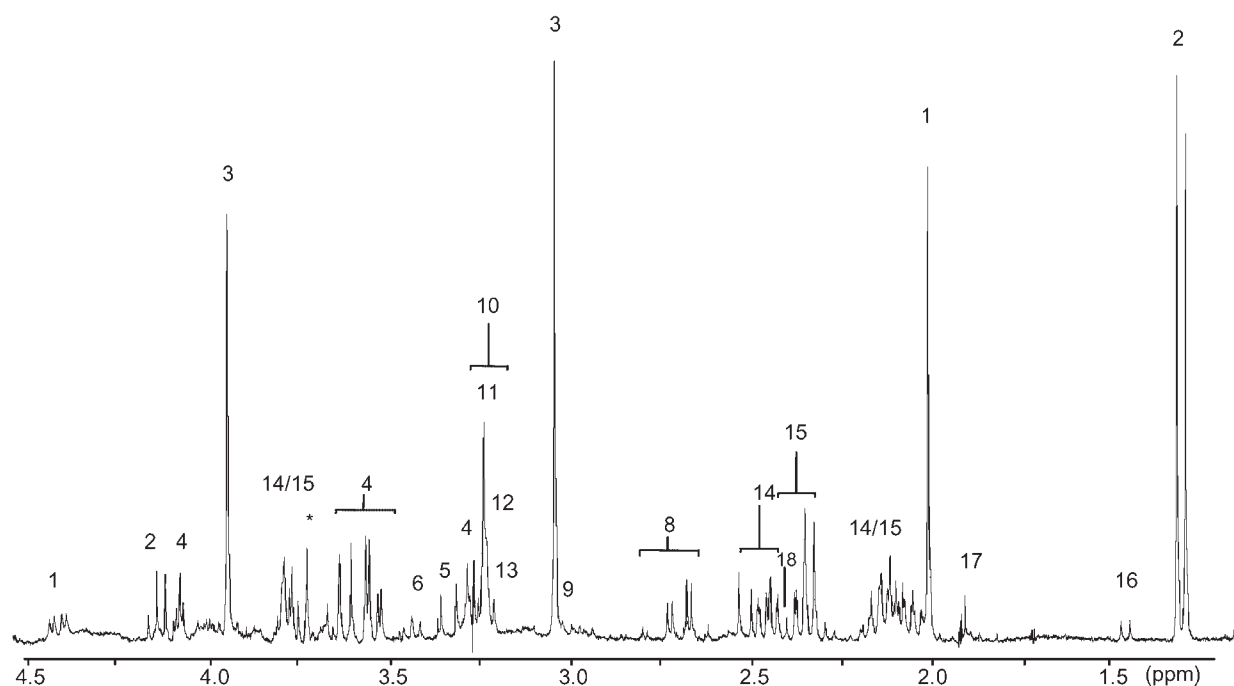


Figure 1. ^1H NMR spectrum of a sample of peritumoral non-neoplastic brain tissue. Note the prominent NAA signal, representative of neuronal tissue, and the well-resolved Asp and myo-Ino signals. The high Lac signal is due to the anaerobic glycolysis during the short period between tissue excision at the time of surgery and freezing in liquid nitrogen. Assignment of all resonance signals follows the compilation in Table 2

were as follows (Tables 3 and 4). Characteristic features of glioblastomas were significantly increased concentrations of Ala ($p = 0.0048$) and metabolite ratios of Gly/tCr and Glu/Gln ($p = 0.0001$ and 0.0043 , respectively) compared with the respective levels in astrocytomas. The

signal multiplet of myo-Ino was well resolved in most of the astrocytoma spectra, in contrast to glioblastomas, but quantification could not be performed accurately enough because of overlapping resonances and poor signal resolution in glioblastoma samples.

Table 2. Resonance assignments of ^1H NMR spectra to metabolites (chemical shift in ppm; ppm values in bold were used for quantification of the respective metabolites)

Metabolite	Abbreviation	Chemical shift ^a	Spin-spin ^b	Proton(s)
1 <i>N</i> -Acetylaspartate	NAA	2.02; 4.39	S; DD	CH ₃ ; αCH_2
2 Lactate	Lac	1.33; 4.11	D; Q	βCH_3 ; αCH
3 Creatine	tCr	3.04 ; 3.93	S; S	N-CH ₃ ; CH ₂
4 myo-Inositol	myo-Ino	3.54; 3.29; 4.05	M; T; T	H1, H3; H5; H2
5 scyllo-Inositol	—	3.35	S	—
6 Taurine	Tau	3.42; 3.27	T; T	N-CH ₂ ; S-CH ₂
7 Glycine	Gly	3.56	S	CH ₂
8 Aspartate	Asp	2.80	M	βCH_2
9 Gamma-aminobutyrate	GABA	1.91; 2.30; 3.01	M; T; T	αCH_2 ; γCH_3 ; βCH_2
10 Choline group	tCho	3.20–3.24	—	—
11 Glycerophosphocholine	GPCho	3.24	S	N-(CH ₃) ₃
12 Phosphocholine	PCho	3.22	S	N-(CH ₃) ₃
13 Free choline	fCho	3.20	S	N-(CH ₃) ₃
14 Glutamine	Gln	2.46 ; 2.13; 3.77	DT; M; M	γCH_2 ; βCH_2 ; αCH
15 Glutamate	Glu	2.35 ; 2.09; 3.75	DT; M; M	γCH_2 ; βCH_2 ; αCH
16 Alanine	Ala	1.48 ; 3.76	D; D	αCH ; βCH_3
17 Acetate	—	1.92	S	CH ₃
18 Succinate	Succ	2.40	S	CH ₂
Unidentified signal	—	3.72	S	—

^aChemical shift is measured with respect to 3-trimethylsilylpropionate (TSP) at 0 ppm.

^bThe letter appended to the chemical shift values indicates whether the signal is a singlet (S), doublet (D), doublet of a doublet (DD), triplet (T), doublet of a triplet (DT), quadruplet (Q) or multiplet (M).³²

Table 3. Metabolite concentrations of primary and recurrent human brain tumors ($\mu\text{mol/g}$, mean \pm SD)

Metabolite	Astrocytomas ($n = 22$) ^a		Glioblastomas ($n = 11$)		Meningiomas ($n = 13$)	
	Primary	Recurring	Primary	Recurring	Primary	Recurring
Gly	0.28 \pm 0.42	1.21 \pm 1.84	3.26 \pm 7.83	5.46 \pm 14.4	1.74 \pm 2.51	2.51 \pm 2.85
tCho	1.20 \pm 1.28	1.71 \pm 1.76	2.08 \pm 3.00	1.86 \pm 2.31	1.45 \pm 1.03	1.74 \pm 1.54
tCr	2.55 \pm 4.05	2.03 \pm 2.26	1.57 \pm 1.67	2.28 \pm 2.09	0.70 \pm 0.51	1.32 \pm 1.19
Glu	0.19 \pm 0.43	0.89 \pm 1.21	1.56 \pm 2.51	3.04 \pm 3.96	2.15 \pm 2.79	3.90 \pm 4.42
Gln	3.94 \pm 4.65	4.82 \pm 4.77	4.25 \pm 5.21	4.11 \pm 5.12	6.20 \pm 4.02	6.69 \pm 6.71
Ala	0.34 \pm 0.48	0.77 \pm 0.81	2.45 \pm 4.23	1.88 \pm 2.70	3.45 \pm 2.85	3.69 \pm 3.60
Gly/tCr	0.19 \pm 0.31	1.00 \pm 1.46	1.43 \pm 1.40	1.32 \pm 2.11	3.06 \pm 2.17	2.79 \pm 2.57
tCho/tCr	0.60 \pm 0.29	1.08 \pm 0.54	1.07 \pm 0.46	0.87 \pm 0.34	2.68 \pm 2.07	2.22 \pm 1.57
Ala/tCr	0.25 \pm 0.38	0.93 \pm 1.18	1.36 \pm 0.82	1.13 \pm 1.13	5.74 \pm 4.03	4.56 \pm 4.66
Glu/Gln	0.06 \pm 0.16	0.27 \pm 0.32	0.58 \pm 0.63	0.61 \pm 0.53	0.42 \pm 0.43	0.47 \pm 0.37

^aPrimary tumors WHO Grade I/II–III, recurrences WHO Grade II–IV.

Table 4. *p*-Values for comparisons between primary tumors and their recurrences of three tumor types and among primary tumors to distinguish among the three tumor types

Metabolite	Astrocytomas	Glioblastomas	Meningiomas	Comparisons among primary tumor types
Gly	0.029 ^a	0.312	0.477	0.1613
tCho	0.034 ^a	0.578	0.671	0.4513
tCr	0.364	0.158	0.710	0.2209
Glu	0.015 ^a	0.278	0.239	0.0209; ^b for astrocytomas–meningiomas
Gln	0.360	0.959	0.514	0.4009
Ala	0.002 ^a	0.354	0.997	0.0048; ^b for astrocytomas–glioblastomas; astrocytomas–meningiomas
Gly/tCr	0.033 ^a	0.773	0.695	0.0001; ^b for all three comparisons
tCho/tCr	0.001 ^a	0.183	0.506	0.0001; ^b for astrocytomas–meningiomas; glioblastomas–meningiomas
Ala/tCr	0.009 ^a	0.594	0.681	0.0001; ^b for astrocytomas–meningiomas; glioblastomas–meningiomas
Glu/Gln	0.016 ^a	0.876	0.790	0.0043; ^b for astrocytomas–glioblastomas; astrocytomas–meningiomas

^aPaired *t*-test, two-tailed, $p < 0.05$ (primary vs recurrent tumor).

^bOne-way ANOVA, *F*-test, $p < 0.05$ (primary tumors of the three tumor types).

Relative to astrocytomas, meningiomas showed significantly higher levels of Ala ($p = 0.0048$) and reduced contents of tCr, reflected by all ratios with respect to tCr. Absolute concentrations of Glu ($p = 0.02$) and the ratio Glu/Gln ($p = 0.0043$) were significantly elevated in meningiomas relative to astrocytomas. No signals of myo-Ino were detectable in meningiomas.

There was no noticeable difference in tCho concentration between the three tumor types. The significantly increased ratio of tCho/tCr ($p = 0.0001$) in meningiomas relative to gliomas was mainly attributed to the diminished tCr content.

Distinction between primary and recurrent meningiomas

The spectrum of the recurrent meningioma (Fig. 2) showed features nearly identical with those of the primary tumor, with a lowered or undetectable Cr signal and a prominent doublet of Ala as the two main features of meningiomas. The absence of myo-Ino allowed the quantification of even low Gly levels. No significant differences between primary and recurrent tumors of 13 patients could be detected.

Distinction between primary and recurrent glioblastomas

Proton spectra of glioblastomas showed high variability between primary tumor and recurrence, often accompanied by substantial deterioration of signal-to-noise ratios, whereas the Gly signal often remained significant (Fig. 3). Both spectra showed notable Ala and Glu signals. There were no significant detectable differences between primary and recurrent glioblastomas of 11 patients.

Distinction between primary and recurrent astrocytomas

Representative spectra of a primary and its recurrent astrocytoma, without malignant transformation in histopathological grading, are displayed in Fig. 4. Remarkable alterations between these spectra were characterized as follows: signals of Gly, Ala and Glu were increased, the ratio tCho/tCr was moderately elevated and the myo-Ino multiplet was unchanged.

Proton spectra of 22 patients with recurrent astrocytomas showed distinctive differences in comparison with their primary occurrences (Fig. 5). The signals of Gly

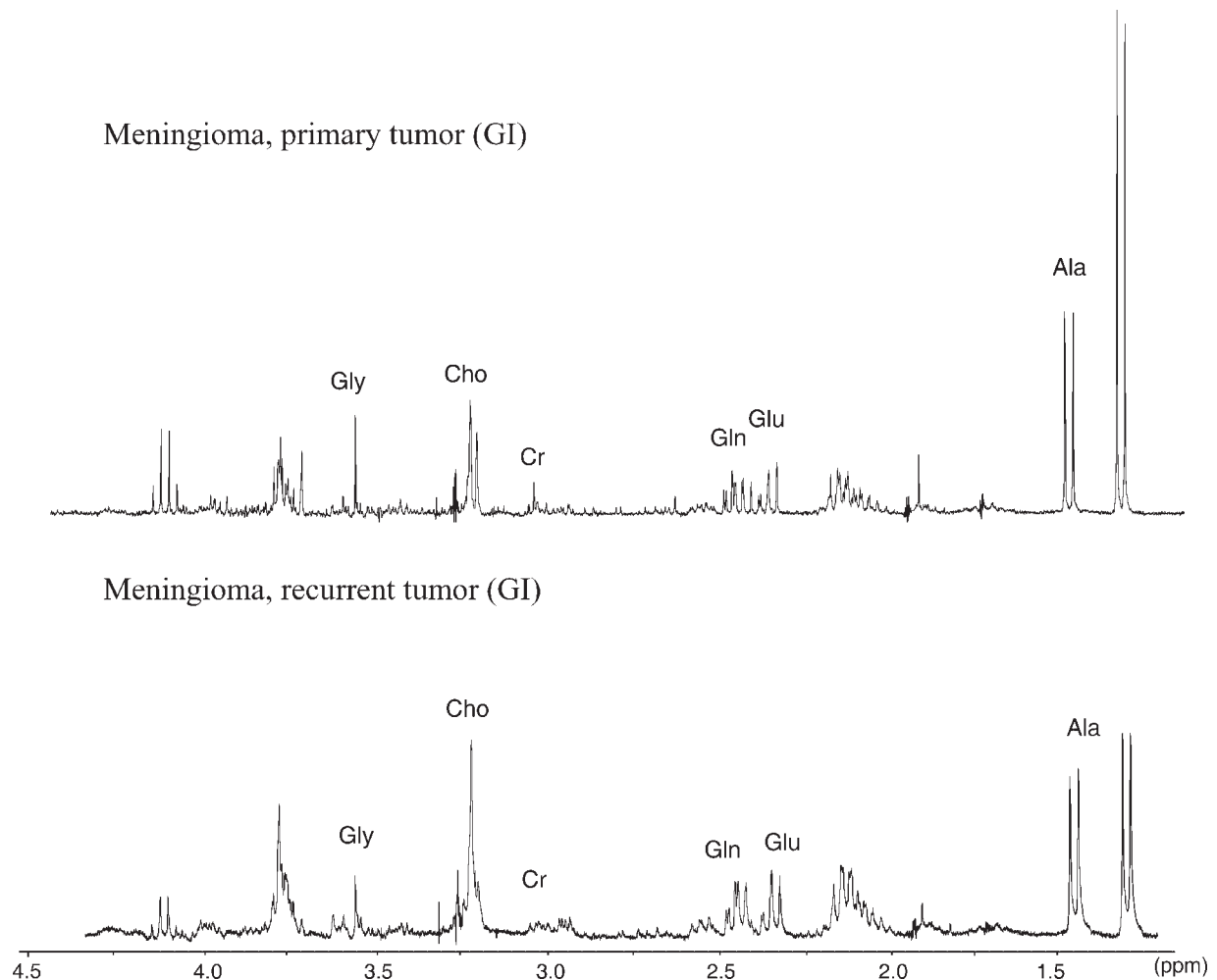


Figure 2. ^1H NMR spectra of a sample of primary and recurrent tumor of a 35-year-old patient presenting with a meningioma. Surgery of the recurrence was performed 4 months after removal of the primary tumor. Note the prominent Ala signal and the diminutive tCr signal. Assignment of all resonance signals follows the compilation in Table 2

($p = 0.029$), tCho ($p = 0.034$), Glu ($p = 0.015$) and Ala ($p = 0.002$) increased with statistical significance. The same holds true for ratios of Ala, Gly and tCho over tCr and of Glu over Gln ($p = 0.009, 0.033, 0.001$ and 0.016 , respectively).

As shown above, Ala, Gly/tCr and Glu/Gln were likewise significantly increased in primary tumors of glioblastomas relative to astrocytomas. To establish whether the observable changes in recurrent astrocytomas were due to samples with increased grading in recurrence, the 22 patients with astrocytomas were further divided into three subgroups according to histopathological grading changes of the respective recurrence (Table 1).

Recurrences of low-grade astrocytomas: grading independent changes in metabolite patterns

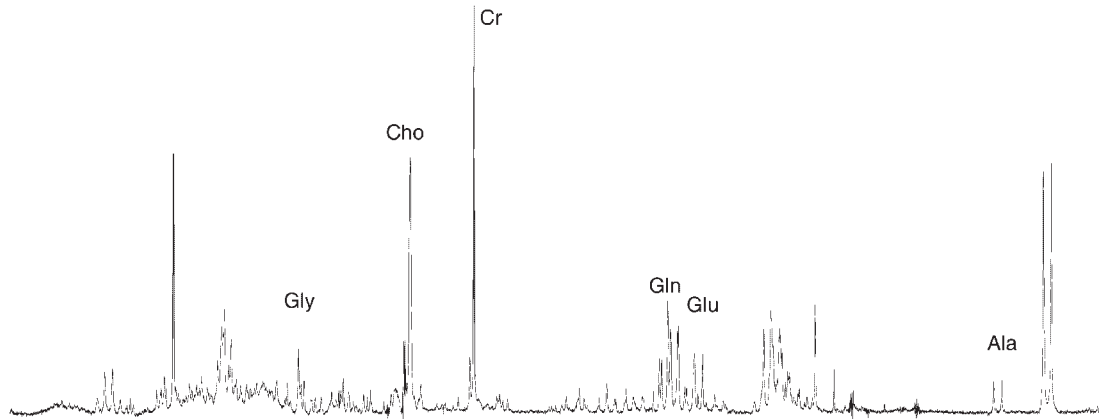
Despite unchanged grading, the recurrent low-grade astrocytomas ($n = 11$) showed similar metabolite patterns

to the more malignant gliomas. In the case of the ratio tCho/tCr, which is a commonly used metabolite ratio for *in vivo* ^1H MRS measurements of brain tumors, a significant increase ($p = 0.0051$) from the low-grade primary (0.5 ± 0.15) to their low-grade recurrent tumors (1.11 ± 0.55) was found (Fig. 6). The same holds for concentrations of Ala (0.24 ± 0.36 vs 0.58 ± 0.73 $\mu\text{mol/g}$; $p = 0.037$) and Glu (0.0 vs 0.35 ± 0.59 $\mu\text{mol/g}$; $p = 0.0032$) with statistical significance. Thus, even in recurrent low-grade astrocytomas, alterations of metabolite patterns representative for high-grade gliomas were observed.

DISCUSSION

The results of the present study emphasize the ability of *in vitro* high-resolution proton NMR spectroscopy to distinguish between different brain tumor tissue types. Moreover, this approach facilitates the detection of subtle changes in tumor metabolism towards higher malignancy

Glioblastoma, primary tumor (GIV)



Glioblastoma, recurrent tumor (GIV)

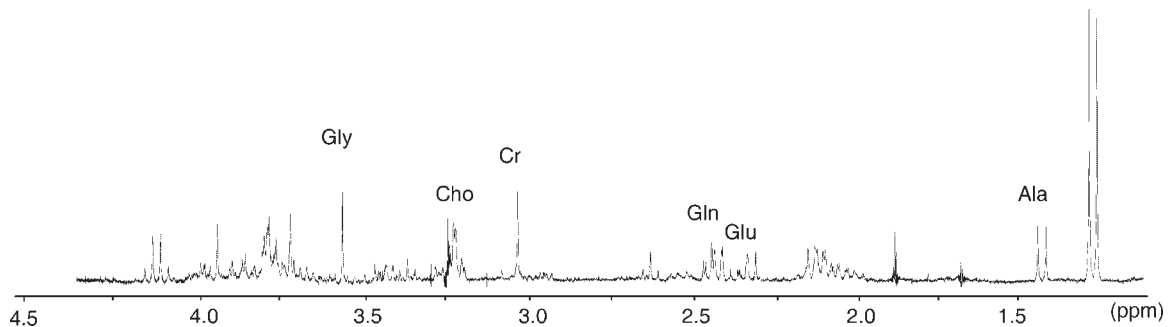


Figure 3. ^1H NMR spectra for a 44-year-old patient presenting with a glioblastoma. Operation of the recurrence was performed 5 months later. The primary and recurrent tumor show pronounced Gly and Ala signals, whereas myo-Ino is diminished. The remaining NAA signal is due to infiltrative growth of tumor tissue

even in recurrent low-grade astrocytomas without histopathological grading changes, reflecting an evolving tumor metabolism. In contrast to previous *in vitro* studies, we found evidence that the widely accepted use of *in vivo* ^1H MRS tCho characteristics, indicative of tumor malignancy and progression, could be confirmed by *in vitro* ^1H MRS, if serial measurements are accomplished.

Mean values found in previous studies using *in vitro* ^1H MRS on non-neoplastic brain, gliomas of various grading classes and meningiomas^{10,12,20,35–37} are compiled in Table 5. Interestingly, the range of literature values for low-grade gliomas covers our mean values of tumor grouping into low-grade primary vs low-grade recurrent tumor. Therefore, inclusion of primary and recurrent tumor status in low-grade gliomas may contribute to the scatter of values found for this tumor entity in the literature.

Non-neoplastic peritumoral brain

The interpretation of spectral characteristics derived from peritumoral non-neoplastic brain tissue should be done with great care. One has to keep in mind that metabolic

alterations in the vicinity of tumor tissue cannot be ruled out. This can be due to peritumoral edema or even histologically non-perceptible changes that could influence spectral features. However, the spectrum obtained in the present study showed features fully identical with those of brain tissue obtained during seizure surgery^{23,35} and also of other samples of peritumoral brain tissue.^{12,21} In contrast to all examined tumor samples, high contents of NAA and well-resolved signals of Asp were found.

NAA has been described by several groups^{7,12,32} as being localized primarily in neurons and therefore it has been proposed as a marker for neuronal density. Reduced or absent levels of NAA in brain tumors as opposed to normal brain were interpreted as a loss of neurons in the tumor tissue. NAA has further been implicated as being involved in the regulation of protein synthesis, myelin production and metabolism of several neurotransmitters such as Asp or *N*-acetylaspartyl glutamate.³⁸ Only recently, NAA was also found in oligodendrocyte-type 2 astrocyte (O-2A) progenitor cells,³⁹ implying that NAA may contribute at an early stage of brain development to lipid synthesis by providing an important source of acetyl groups.

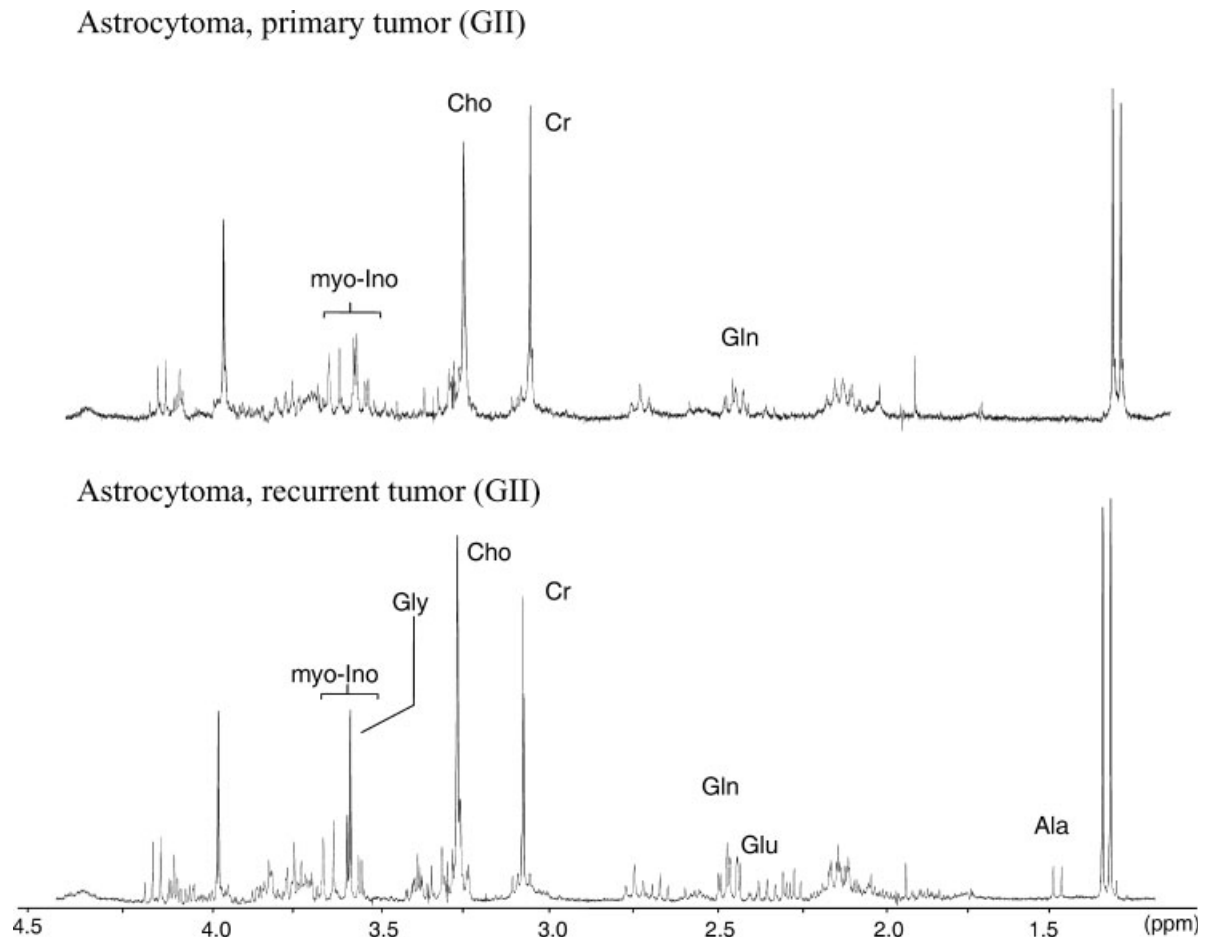


Figure 4. ^1H NMR spectra for a 52-year-old patient presenting with a low-grade astrocytoma and with recurrence of unchanged grading after 2.5 years. The spectrum of the recurrence (below) shows elevated Gly and Ala signals, whereas myo-Ino is unchanged. The ratio tCho/tCr is slightly increased

Asp is diminished in brain tumors but exhibits a well-resolved signal in normal brain, reflecting the interdependence of NAA and Asp.^{23,24,32} The observable NAA and Asp contents appearing in a brain tumor spectra *in vitro* are considered as infiltrative growth of the tumor into adjacent brain or as neuron residues within the tumor tissue.^{13,20,40,41}

Myo-Ino is a further prominent signal in normal brain spectra, and also in the spectra of low-grade gliomas. Some authors suggest myo-Ino to be specific to glial cells, but its role, apart from its biochemical relationship to messenger inositol polyphosphates, or functional role as cell osmoregulator is still unclear.^{42,43}

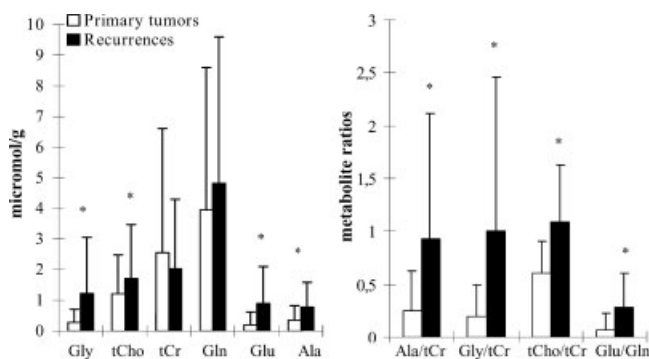


Figure 5. Metabolite concentrations and ratios (mean \pm SD) in 22 patients with astrocytomas (Grade II–IV), reflecting an evolving tumor metabolism in individual tumor progression. Statistical significance is indicated with *; for *p*-values see Table 4

Meningiomas

The discrimination of meningiomas from gliomas is most easily achieved by the low or undetectable Cr content and the prominent Ala doublet at 1.48 ppm in meningiomas. Cr reduction and high Ala contents are also found in cell cultures of normal meningeal cells.¹⁹ Hence a low Cr level is not a sign of impaired energy supply but may be a result of a different steady-state energy metabolism compared with brain tissue.¹⁵ A further feature of meningiomas is the absence of myo-Ino in comparison with gliomas.²⁰

Patients examined in the present study experienced recurrence after a mean of 15 months. Since malignant transformation and infiltrative growth are rare, this short recurrence period may be influenced by incomplete

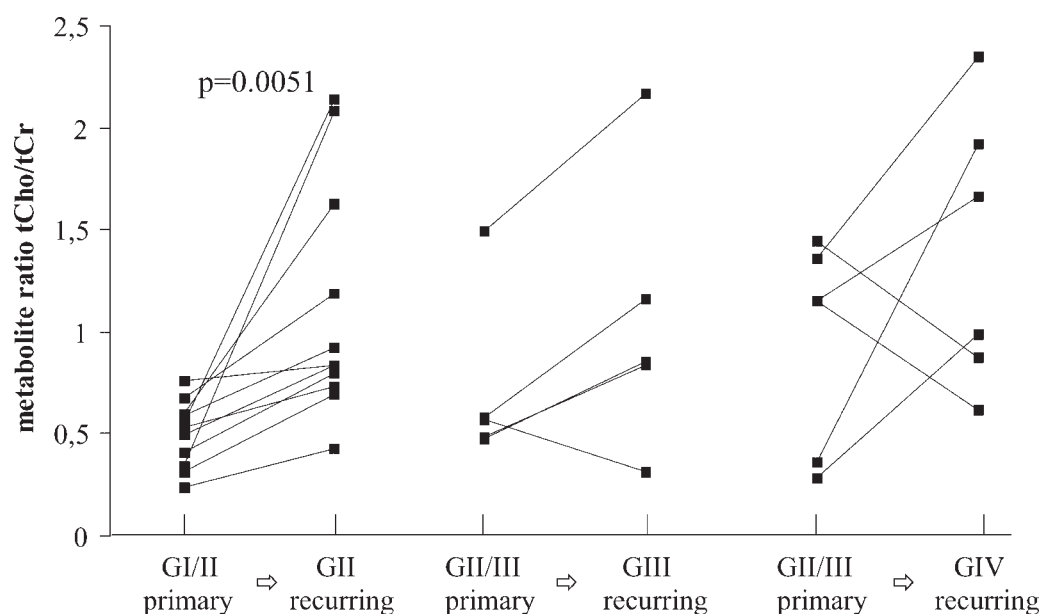


Figure 6. Intraindividual alterations of the tCho/tCr ratio as a function of malignant transformation in primary and recurrent astrocytomas, as based on the WHO histopathological classification. The consistently increasing ratios display no distinction according to tumor grade. Low-grade astrocytomas without malignant transformation ($n = 11$, left panel) showed a statistically significant, elevated ratio for the recurrent tumor ($p = 0.0051$), which is not yet visible in histological analysis based on morphological criteria

Table 5. ^1H MRS quantitative results derived from previous studies (PCA extraction of tissue extracts) of peritumoral brain, low-grade (Grades I–II) and high-grade (Grades III–IV) gliomas and meningiomas ($\mu\text{mol/g}$)

Metabolite	Normal brain	Grade I–II	Own values ^a	Grade III–IV	Own values ^a	Meningiomas	Own values ^a
Gly	0.66–0.82 ^{b,f,g}	0.91–1.77 ^{b,e,f}	0.12–0.70	1.53–5.01 ^{b,e}	0.45–5.46	1.01–1.60 ^{b,e}	1.74–2.51
tCho	0.57–1.86 ^{b,c,e–g}	0.68–1.77 ^{b,c,e,f}	1.03–1.70	1.19–2.18 ^{b,c,e}	0.82–2.08	0.81–1.92 ^{b,c,e}	1.45–1.74
tCr	2.17–10.76 ^{b–g}	1.94–7.80 ^{b–f}	1.8–2.62	1.85–3.65 ^{b–e}	1.13–2.28	0.42–1.45 ^{b–e}	0.70–1.32
Ala	0.14–0.91 ^{b,e–g}	0.37–1.01 ^{b,e,f}	0.24–0.58	0.92–3.25 ^{b,e}	0.79–2.45	1.27–3.1 ^{b,e}	3.45–3.69

^aMean values of tumor grouping as described above.

^bKinoshita and Yokota.³⁶

^cUsenius *et al.*²¹

^dGill *et al.*¹²

^ePeeling and Sutherland.²⁰

^fSutton *et al.*³⁷

^gPetroff *et al.*³⁵

resection due to tumor localization. The spectra between primary and recurrent meningiomas were strikingly unchanged, indicating no metabolic alterations in the course of the recurrence development.

Glioblastomas

Glioblastomas are known to be the most heterogeneous tumors in the brain, with a variable content of necrosis, cell density, vascular proliferation and surrounding edema.²⁹ Accordingly, the spectral patterns of primary and recurrent glioblastomas showed high variability, extending from indications of diffusely infiltrative growth, reflected by high NAA and Asp contents, to signs of tissue necrosis, with diminished metabolite signals. Nevertheless, glioblastomas could be distin-

guished from astrocytomas by specific metabolic patterns. The most noticeable peculiarity is the Gly singlet at 3.56 ppm.^{14,20,36} It is suggested that intermediates of the more active glycolytic pathway in tumors bring about an increased Gly concentration, involving phosphoglycerate and serine.⁴⁴ Since the scatter of absolute values was rather high, focus was on the relative Gly concentration (normalized to tCr), which was found to be statistically significantly different from that of astrocytomas. Furthermore, the concentration of Ala and the ratio Glu/Gln were significantly higher in glioblastomas than in astrocytomas. Florian *et al.* described increased Ala and Glu contents in defective or transformed cells due to enzymatic alterations in the glycolytic pathway in brain tumors.³³ Neither tCho nor the tCho/tCr ratio was found to be discriminative between primary tumors of astrocytomas and glioblastomas.

The postoperative interval was <1 year, reflecting the tendency for fast tumor progression. No significance in metabolite concentrations or relative values could be ascertained between primary and recurrent glioblastomas.

Astrocytomas

In the present study, astrocytomas reoccurred after a mean of 22 months, presenting further malignant degeneration in half of the investigated cases. The number of observed transformations is in good agreement with previous studies on the frequency of malignant transformation in gliomas.²⁸

Earlier *in vitro* ¹H MRS investigations^{12,20,21,36,37,41} focusing solely on the distinction of low- and high-grade gliomas are in full agreement with the differences found in the present study. Here, however, these differences are solidified by basing them on the *intra-individual* distinction between primary and recurrent astrocytomas: concentrations of Ala, tCho, Gly, Glu and ratios of Gly, tCho and Ala to tCr and of Glu to Gln increased significantly between primary and recurrent gliomas. In the case of Ala and Gly to tCr and Glu to Gln ratios, the values were also found to be discriminative inter-individually, on comparing primary tumors of astrocytomas and glioblastomas.

Choline findings

The *in vivo* tCho characteristics were not found to be directly and unambiguously transferable to the *in vitro* findings. For once, there is still no consensus about the chemical species responsible for the tCho peak *in vivo*. *In vitro* ¹H MRS measurements of brain tumor tissue showed lower tCho contents than expected from *in vivo* measurements performed prior to tumor excision.^{10,14} This was related, at least partly, to significant amounts of glycerophospholipids with mobile choline headgroups under *in vivo* conditions.^{20,45} Furthermore, the tCho content, as determined by *in vitro* ¹H MRS, does not seem to be a reliable parameter either for the distinction of normal brain tissue from brain tumors or for the differentiation of low-grade from high-grade gliomas.^{10,12,33,36} In fact, our study confirmed the unreliability of the tCho content and the ratio tCho/tCr for the distinction between primary occurrences of astrocytomas and glioblastomas.

Specific issues concerning recurrence discriminations

Interestingly, in contrast to the doubtful diagnostic relevance of tCho as discussed above, *serial* measurements of tCho content and tCho/tCr ratio showed a statistically

significant increase on comparing primary and recurrent astrocytomas. Moreover, even low-grade astrocytomas (Fig. 6) showed a significantly elevated metabolite ratio of tCho/tCr in recurrence despite an unchanged WHO grading ($p = 0.0051$). Since histopathological grading of the respective sample volume yielded no change in tumor categorization, the detected spectroscopic features are believed to occur at an early stage of malignant transformation, which is not yet observable morphologically but which is detectable in metabolic alterations. Support for this view comes from serial *in vivo* ¹H MRS measurements after gamma knife radiosurgery of malignant gliomas by Graves *et al.*⁴⁶ The increase in Cho signal indicative of tumor recurrence preceded a deterioration of MR imaging criteria by 1–2 months. Tedeschi *et al.*³ investigated patients with gliomas repeatedly, using *in vivo* ¹H MRS, in order to discriminate clinically stable brain tumors from those progressing as a result of low- to high-grade malignant transformation. Analysis of the tCho signal intensity showed a clear increase in all progressive cases or in recurrences of previously treated tumors. This was associated by the authors with reduced survival times, indicating that categorization by means of serial ¹H MRS studies was accurate.

In a study by our group published previously, we investigated human brain tumor samples using a double extraction method, which enabled us to quantify both water-soluble and lipophilic spectral Cho-containing components of the same sample volume.⁴⁷ Evaluation of phospholipid profiles in recurrent astrocytomas showed increased malignancy in comparison with their primary occurrence, namely, the relative concentration of phosphatidylcholine (PtdCho), the most abundant membrane lipid and the major component in Cho metabolism, was 15% higher in recurrent astrocytomas than their primary tumors ($p = 0.0103$), whereas the second Cho-containing phospholipid sphingomyelin (SM) decreased by 23% ($p = 0.0314$). The same composition was found on comparing samples of primary astrocytomas and primary glioblastomas: PtdCho was found to be 34% higher in primary glioblastomas than in primary astrocytomas ($p = 0.0003$), whereas SM decreased by 50% ($p = 0.0061$). We concluded that the alterations in phospholipid composition in recurrent astrocytomas were related to malignant transformation. Our present ¹H NMR investigations of the water-soluble tissue fraction provide insights into the choline metabolism during malignant transformation. We found that the ratio tCho/tCr was significantly increased in recurrent astrocytomas and also in the comparison between primary astrocytomas and primary glioblastomas.

CONCLUSIONS

The consecutive assessment of tumor metabolism by *in vitro* ¹H MRS studies of individual patients by means

of serial measurements, eliminates influences of inter-individual tumor heterogeneity. Using this diagnostic approach, remarkable peculiarities of an evolving tumor metabolism even at an early stage of malignant transformation are detectable. In contrast to several previous *in vitro* studies but in good agreement with previous *in vivo* studies, the present investigation led to a correlation of the tCho signal and the ratio tCho/tCr with tumor progression in gliomas. Further *in vitro* MRS studies should be performed to elucidate the interrelation of cell membrane and cytosolic choline metabolism during malignant transformation.

Acknowledgements

The authors are grateful for helpful discussions with Prof. J. Hahn and Dr K. Raffelt, University of Cologne, concerning methods of quantification.

REFERENCES

- Negendank W. Studies of human tumors by MRS: a review. *NMR Biomed.* 1992; **5**: 303–324.
- Bruhn H, Frahm J, Gyngell ML, Merboldt KD, Hanicke W, Sauter R, Hamburger C. Noninvasive differentiation of tumors with use of localized H-1 MR spectroscopy *in vivo*: initial experience in patients with cerebral tumors [see comments]. *Radiology* 1989; **172**: 541–548.
- Tedeschi G, Lundbom N, Raman R, Bonavita S, Duyn JH, Alger JR, Di C. Increased choline signal coinciding with malignant degeneration of cerebral gliomas: a serial proton magnetic resonance spectroscopy imaging study. *J. Neurosurg.* 1997; **87**: 516–524.
- Vigneron D, Bollen A, McDermott M, Wald L, Day M, Moyher-Noworolski S, Henry R, Chang S, Berger M, Dillon W, Nelson S. Three-dimensional magnetic resonance spectroscopic imaging of histologically confirmed brain tumors. *Magn. Reson. Imaging* 2001; **19**: 89–101.
- Howe FA, Opstad KS. ¹H MR spectroscopy of brain tumours and masses. *NMR Biomed.* 2003; **16**: 123–131.
- Freeman JJ. Regulatory mechanisms of choline production. *Life Sci.* 1996; **58**: 1921–1927.
- Miller BL. A review of chemical issues in ¹H NMR spectroscopy: N-acetyl-L-aspartate, creatine and choline. *NMR Biomed.* 1991; **4**: 47–52.
- Miller BL, Chang L, Booth R, Ernst T, Cornford M, Nikas D, McBride D, Jenden DJ. *In vivo* ¹H MRS choline: correlation with *in vitro* chemistry/histology. *Life Sci.* 1996; **58**: 1929–1935.
- Podo F. Tumour phospholipid metabolism. *NMR Biomed.* 1999; **12**: 413–439.
- Usenius JP, Vainio P, Hernesniemi J, Kauppinen RA. Choline-containing compounds in human astrocytomas studied by ¹H NMR spectroscopy *in vivo* and *in vitro*. *J. Neurochem.* 1994; **63**: 1538–1543.
- Shimizu H, Kumabe T, Shirane R, Yoshimoto T. Correlation between choline level measured by proton MR spectroscopy and Ki-67 labeling index in gliomas. *AJNR Am. J. Neuroradiol.* 2000; **21**: 659–665.
- Gill SS, Thomas DG, Van Bruggen N, Gadian DG, Peden CJ, Bell JD, Cox JJ, Menon DK, Iles RA, Bryant DJ. Proton MR spectroscopy of intracranial tumours: *in vivo* and *in vitro* studies. *J. Comput. Assist. Tomogr.* 1990; **14**: 497–504.
- Negendank WG, Sauter R, Brown TR, Evelhoch JL, Falini A, Gotsis ED, Heerschap A, Kamada K, Lee BC, Mengeot MM, Moser E, Padavic-Shaller KA, Sanders JA, Spraggins TA, Stillman AE, Terwey B, Vogl TJ, Wicklow K, Zimmerman RA. Proton magnetic resonance spectroscopy in patients with glial tumors: a multicenter study. *J. Neurosurg.* 1996; **84**: 449–458.
- Tugnoli V, Tosi MR, Barbarella G, Bertoluzza A, Ricci R, Trevisan C. *In vivo* ¹H MRS and *in vitro* multinuclear MR study of human brain tumors. *Anticancer Res.* 1996; **16**: 2891–2899.
- Kugel H, Heindel W, Ernestus RI, Bunke J, du Mesnil R, Friedmann G. Human brain tumors: spectral patterns detected with localized H-1 MR spectroscopy. *Radiology* 1992; **183**: 701–709.
- Tate AR, Griffiths JR, Martinez-Perez I, Moreno A, Barba I, Cabanas ME, Watson D, Alonso J, Bartumeus F, Isamat F, Ferrer I, Vila F, Ferrer E, Capdevila A, Arus C. Towards a method for automated classification of ¹H MRS spectra from brain tumours. *NMR Biomed.* 1998; **11**: 177–191.
- Klunk WE, Panchalingam K, Moosy J, McClure RJ, Pettegrew JW. N-Acetyl-L-aspartate and other amino acid metabolites in Alzheimer's disease brain: a preliminary proton nuclear magnetic resonance study. *Neurology* 1992; **42**: 1578–1585.
- Higuchi T, Graham SH, Fernandez EJ, Rooney WD, Gaspary HL, Weiner MW, Maudsley AA. Effects of severe global ischemia on N-acetylaspartate and other metabolites in the rat brain. *Magn. Reson. Med.* 1997; **37**: 851–857.
- Florian CL, Preece NE, Bhakoo KK, Williams SR, Noble MD. Cell type-specific fingerprinting of meningioma and meningeal cells by proton nuclear magnetic resonance spectroscopy. *Cancer Res.* 1995; **55**: 420–427.
- Peeling J, Sutherland G. High-resolution ¹H NMR spectroscopy studies of extracts of human cerebral neoplasms. *Magn. Reson. Med.* 1992; **24**: 123–136.
- Usenius JP, Kauppinen RA, Vainio PA, Hernesniemi JA, Vapalahti MP, Paljarvi LA, Soimakallio S. Quantitative metabolite patterns of human brain tumors: detection by ¹H NMR spectroscopy *in vivo* and *in vitro*. *J. Comput. Assist. Tomogr.* 1994; **18**: 705–713.
- Bruhn H, Michaelis T, Merboldt KD, Hanicke W, Gyngell ML, Hamburger C, Frahm J. On the interpretation of proton NMR spectra from brain tumours *in vivo* and *in vitro*. *NMR Biomed.* 1992; **5**: 253–258.
- Peeling J, Sutherland G. ¹H magnetic resonance spectroscopy of extracts of human epileptic neocortex and hippocampus. *Neurology* 1993; **43**: 589–594.
- Kotitschke K, Jung H, Nekolla S, Haase A, Bauer A, Bogdahn U. High-resolution one- and two-dimensional ¹H MRS of human brain tumor and normal glial cells. *NMR Biomed.* 1994; **7**: 111–120.
- Gill SS, Small RK, Thomas DG, Patel P, Porteous R, Van BN, Gadian DG, Kauppinen RA, Williams SR. Brain metabolites as ¹H NMR markers of neuronal and glial disorders. *NMR Biomed.* 1989; **2**: 196–200.
- Kinoshita Y, Kajiwara H, Yokota A, Koga Y. Proton magnetic resonance spectroscopy of astrocytic tumors: an *in vitro* study. *Neurol. Med.-Chir. (Tokyo)* 1993; **33**: 350–359.
- Roda JM, Pascual JM, Carceller F, Gonzalez-Llanos F, Perez-Higuera A, Solivera J, Barrios L, Cerdan S. Nonhistological diagnosis of human cerebral tumors by ¹H magnetic resonance spectroscopy and amino acid analysis. *Clin. Cancer Res.* 2000; **6**: 3983–3993.
- Laws ERJ, Taylor WF, Clifton MB, Okazaki H. Neurosurgical management of low-grade astrocytoma of the cerebral hemispheres. *J. Neurosurg.* 1984; **61**: 665–673.
- Zülch KJ. *Brain Tumors: Their Biology and Pathology*. Zülch: Berlin, 1986.
- Francavilla TL, Miletich RS, Di CG, Patronas NJ, Rizzoli HV, Wright DC. Positron emission tomography in the detection of malignant degeneration of low-grade gliomas. *Neurosurgery* 1989; **24**: 1–5.
- Kleihues P, Burger PC, Scheithauer BW. The new WHO classification of brain tumours. *Brain Pathol.* 1993; **3**: 255–268.
- Remy C, Arus C, Ziegler A, Lai ES, Moreno A, Le Fur Y, Decors M. *In vivo*, *ex vivo* and *in vitro* one- and two-dimensional nuclear magnetic resonance spectroscopy of an intracerebral glioma in rat brain: assignment of resonances. *J. Neurochem.* 1994; **62**: 166–179.
- Florian CL, Preece NE, Bhakoo KK, Williams SR, Noble M. Characteristic metabolic profiles revealed by ¹H NMR spectroscopy for three types of human brain and nervous system tumours. *NMR Biomed.* 1995; **8**: 253–264.

34. Preston-Martin S. Epidemiology of primary CNS neoplasms. *Neurol. Clinics* 1996; **14**: 273–290.
35. Petroff OA, Spencer DD, Alger JR, Prichard JW. High-field proton magnetic resonance spectroscopy of human cerebrum obtained during surgery for epilepsy. *Neurology* 1989; **39**: 1197–1202.
36. Kinoshita Y, Yokota A. Absolute concentrations of metabolites in human brain tumors using *in vitro* proton magnetic resonance spectroscopy. *NMR Biomed.* 1997; **10**: 2–12.
37. Sutton LN, Wehrli SL, Gennarelli L, Wang Z, Zimmerman R, Bonner K, Rorke LB. High-resolution ^1H -magnetic resonance spectroscopy of pediatric posterior fossa tumors *in vitro*. *J. Neurosurg.* 1994; **81**: 443–448.
38. Birken DL, Oldendorf WH. *N*-Acetyl-L-aspartic acid: a literature review of a compound prominent in ^1H NMR spectroscopic studies of brain. *Neurosci. Biobehav. Rev.* 1989; **13**: 23–31.
39. Urenjak J, Williams SR, Gadian DG, Noble M. Proton nuclear magnetic resonance spectroscopy unambiguously identifies different neural cell types. *J. Neurosci.* 1993; **13**: 981–989.
40. Kuesel AC, Donnelly SM, Halliday W, Sutherland GR, Smith IC. Mobile lipids and metabolic heterogeneity of brain tumours as detectable by *ex vivo* ^1H MR spectroscopy. *NMR Biomed.* 1994; **7**: 172–180.
41. Carpinelli G, Carapella CM, Palombi L, Raus L, Caroli F, Podo F. Differentiation of glioblastoma multiforme from astrocytomas by *in vitro* ^1H MRS analysis of human brain tumors. *Anticancer Res.* 1996; **16**: 1559–1563.
42. Ross BD. Biochemical considerations in ^1H spectroscopy. Glutamate and glutamine; myo-inositol and related metabolites. *NMR Biomed.* 1991; **4**: 59–63.
43. Leibfritz D, Brand A. Multinuclear NMR studies on the energy metabolism of glial and neuronal cells. *J. Neurochem.* 1993; **61**: 5247.
44. Patel AJ, Hunt A. Concentration of free amino acids in primary cultures of neurones and astrocytes. *J. Neurochem.* 1985; **44**: 1816–1821.
45. Michaelis T, Merboldt KD, Hanicke W, Gyngell ML, Bruhn H, Frahm J. On the identification of cerebral metabolites in localized ^1H NMR spectra of human brain *in vivo*. *NMR Biomed.* 1991; **4**: 90–98.
46. Graves EE, Nelson SJ, Vigneron DB, Verhey L, McDermott M, Larson D, Chang S, Prados MD, Dillon WP. Serial proton MR spectroscopic imaging of recurrent malignant gliomas after gamma knife radiosurgery [see comments]. *AJNR Am. J. Neuroradiol.* 2001; **22**: 613–624.
47. Lehnhardt FG, Röhn G, Ernestus RI, Grüne M, Hoehn M. ^1H - and ^{31}P -MR spectroscopy of primary and recurrent human brain tumors *in vitro*: malignancy-characteristic profiles of water soluble and lipophilic spectral components. *NMR Biomed.* 2001; **14**: 307–317.